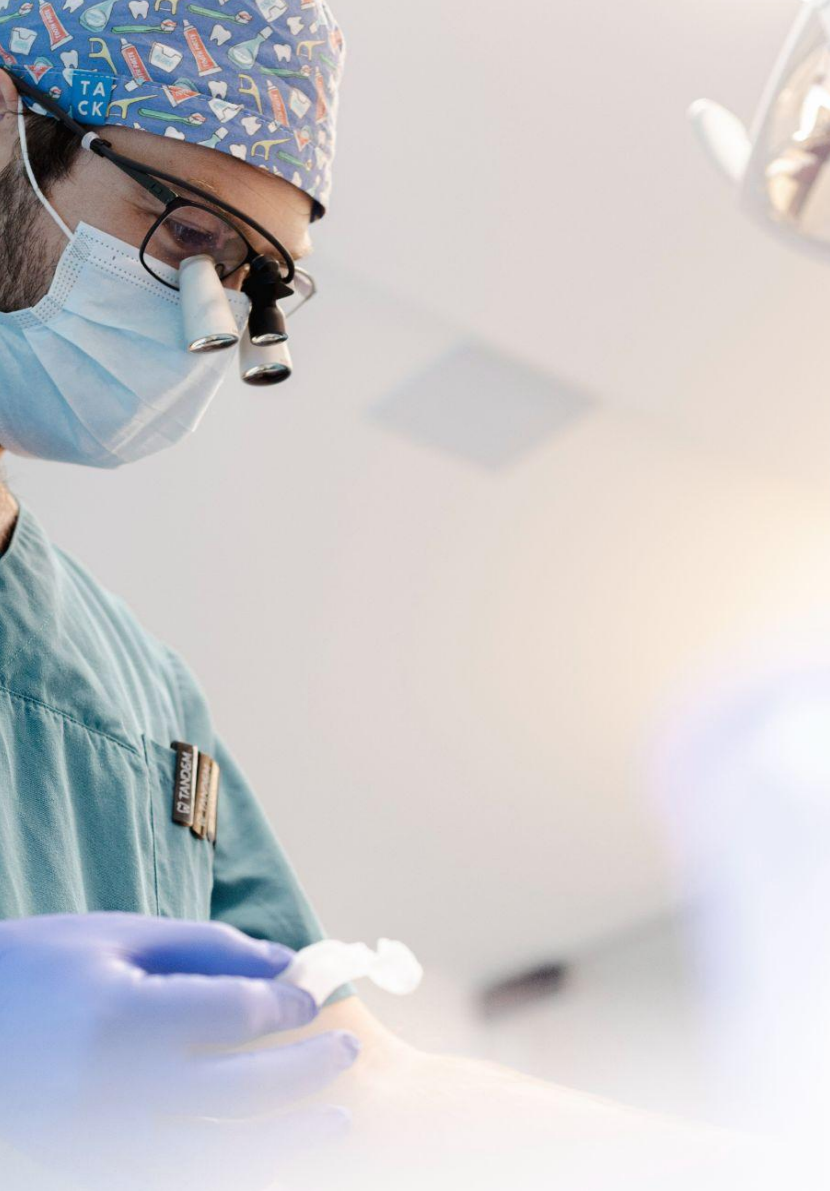
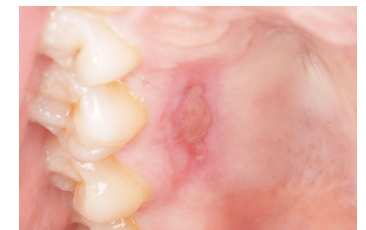
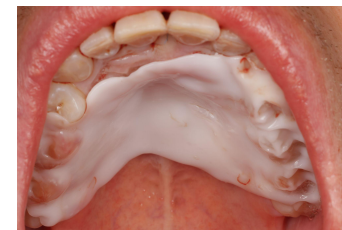
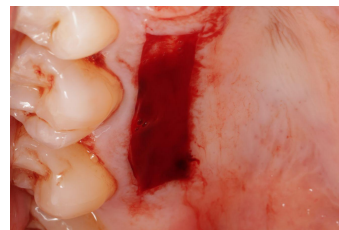
## The Elemental Workflow

to protect the wound after  
harvesting tissue from the palate

Protocol, Scientific Evidence & Cases



*"Since I use Elemental,  
I'm more proud of the care  
our clinic provides."*

Dr. Bo Molemans



## Glossary

### Protocol p.3

Heating the material p.4

Creating the stent p.5

Placing the stent p.9

Post-operative instructions p.10

---

### Science p.12

The technology p.13

In-vitro tests p.14

In-vivo tests p.18

---

### Cases p.21

Contact information p.30

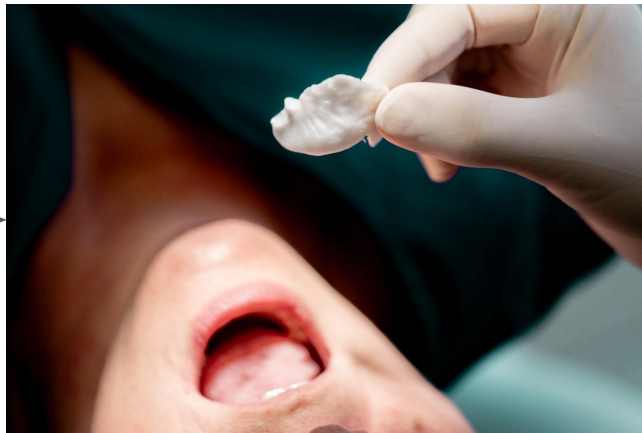---

## Heating the material



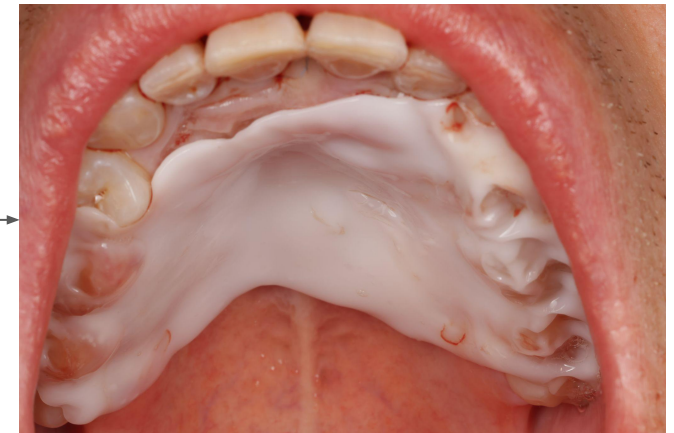- To manipulate the material, it must be heated for 10 seconds.
- This can be done with 80°C water.

## Creating the stent



- The heated material is shaped directly on the palate.
- The material sets & becomes a solid stent in 1-2 minutes.

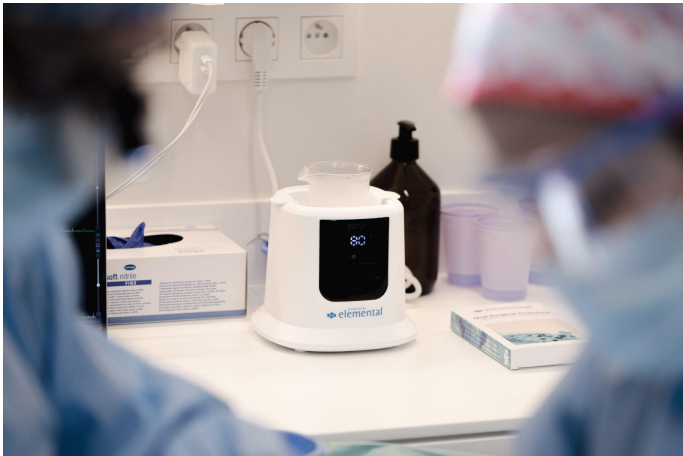## Post-operative instructions



- The patients wear the stent for 7 days post-operatively.
- Pain is minimized & healing accelerates.

**Heating the material** — Creating the stent — Placing the stent — Post-operative instructions

## Heating the material

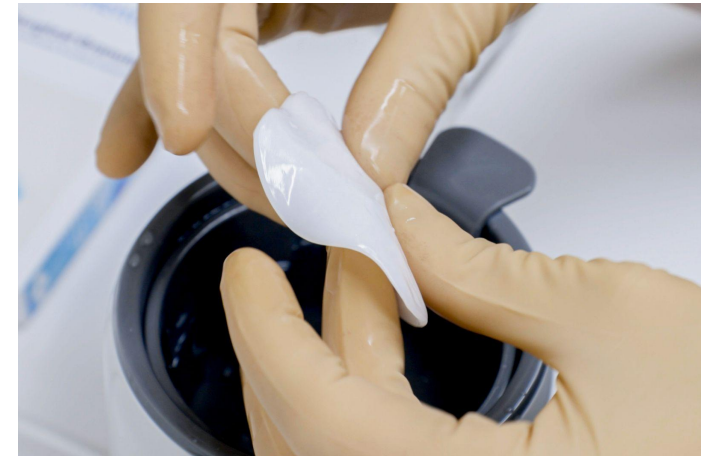

Boil water or use an Elemental waterbath to heat water to 80°C.



Stir the granules for 10 seconds in the heated water.

Dosage: 1 stent takes about 3 grams, which is 1/3 of a packet.



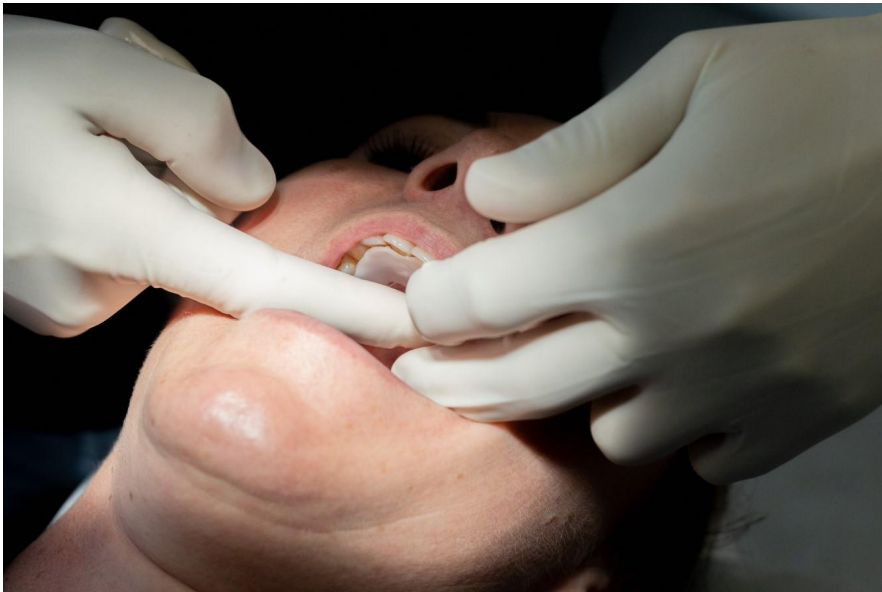The material is now a mass you can mold.

Heating the material — **Creating the stent** — Placing the stent — Post-operative instructions

## Shaping the stent with 2 fittings.

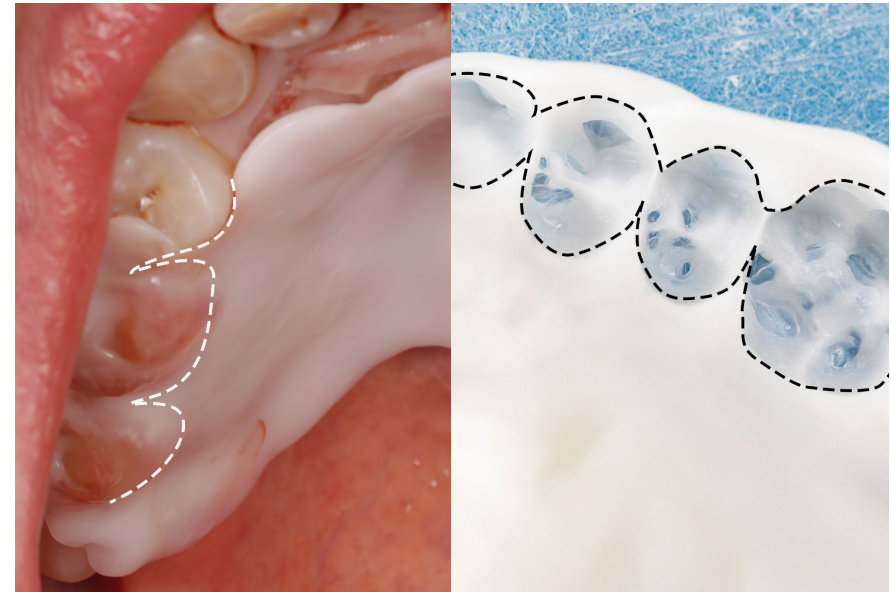
Optimal retention & stability can be achieved by heating & fitting the material twice.

### 1st fitting: getting the general shape



Getting a general shape of the palate & occlusal edge.

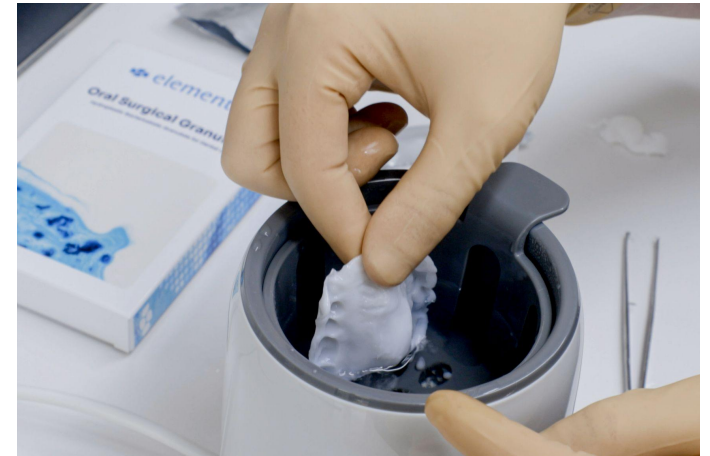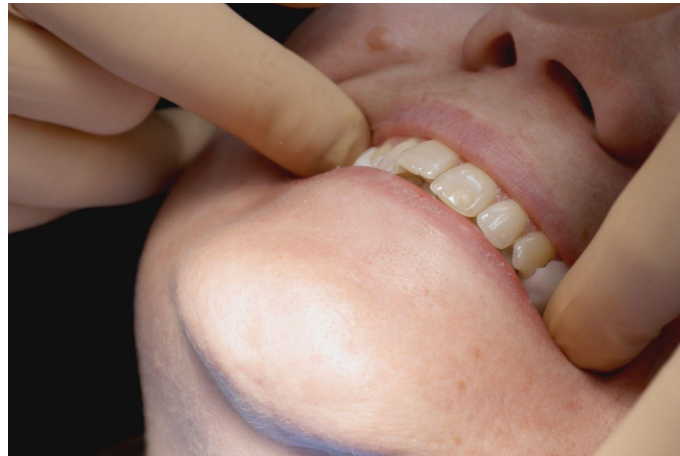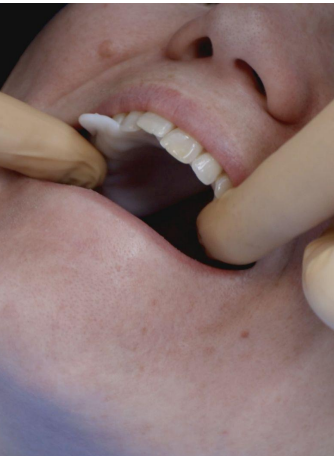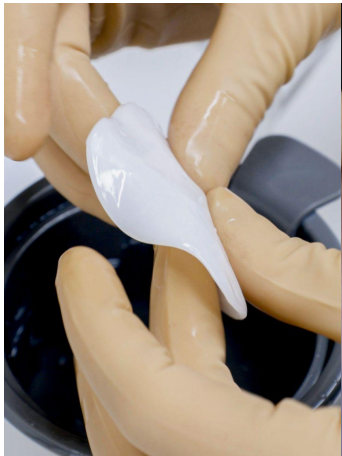### 2nd fitting: getting the details right



Focusing on interproximal & occlusal retention.

Heating the material — **Creating the stent** — Placing the stent — Post-operative instructions

## Fitting #1: Obtaining the general shape



Cover the palate & occlusal surface of the molars with the heated material.

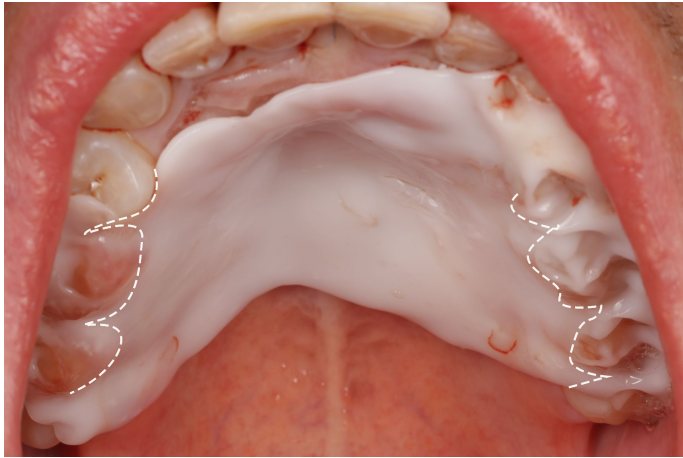
Ask the patient to bite down & wait 1 minute for the material to set.

Reheat the material for about 5 seconds to prepare the 2nd fitting.

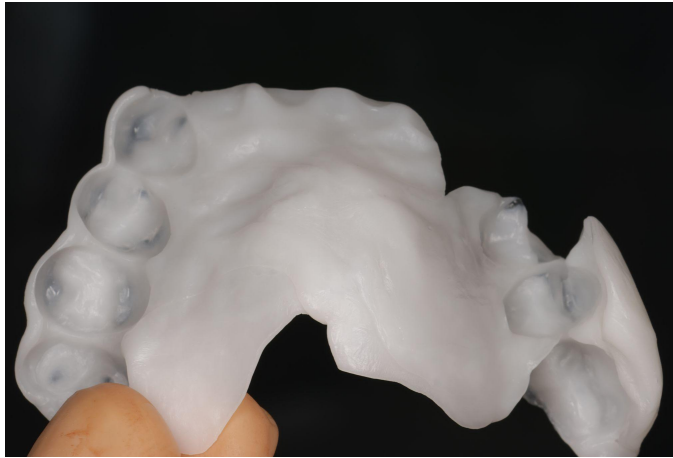**IMPORTANT TIP:** Use the interproximal & occlusal surfaces to get retention.

Heating the material — **Creating the stent** — Placing the stent — Post-operative instructions

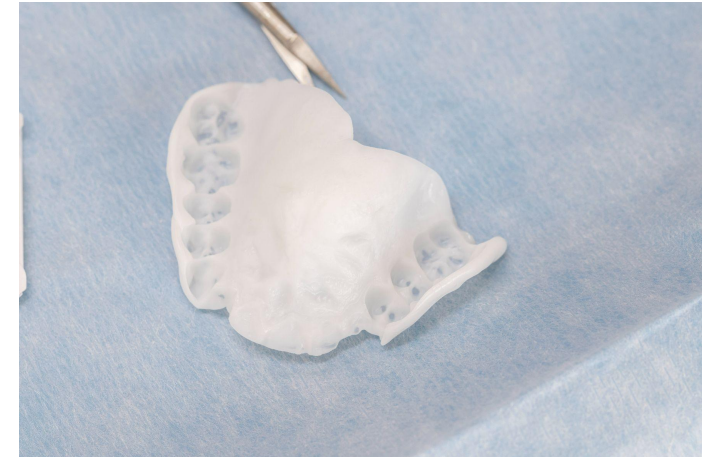## Fitting #2: Getting the details right.



Press the stent into the interproximal areas for extra retention.



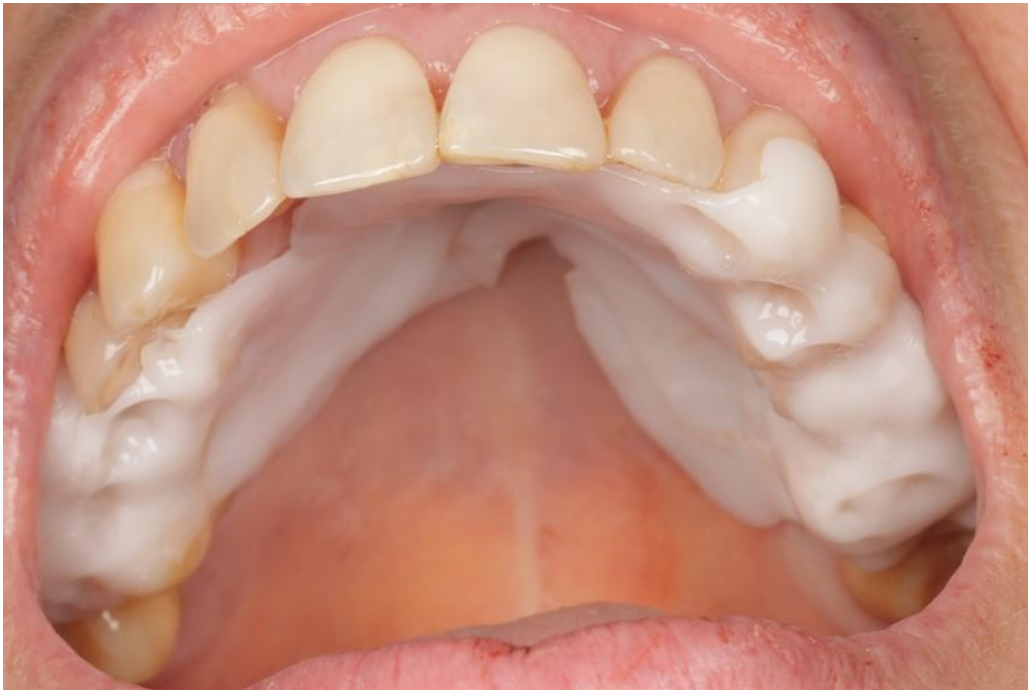Let it set and remove once solid, after 1 minute.



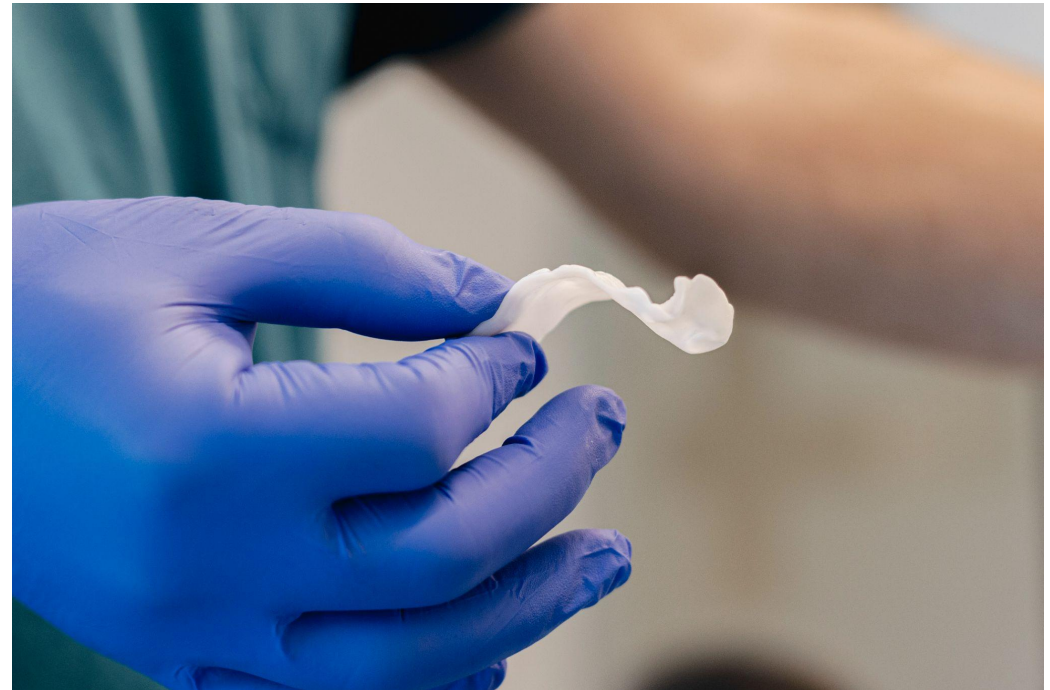Keep it chairside to place it once the graft has been harvested.

Heating the material — **Creating the stent** — Placing the stent — Post-operative instructions

## 2 Quality Checks



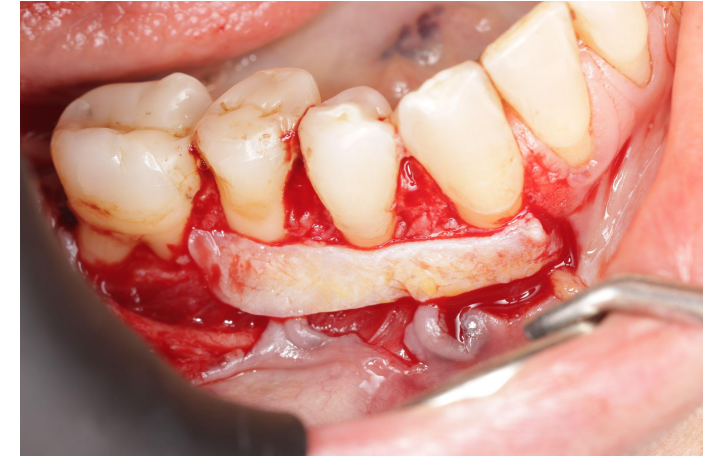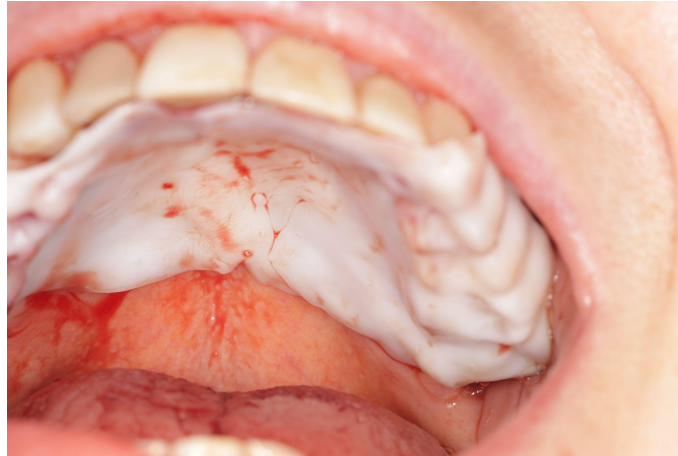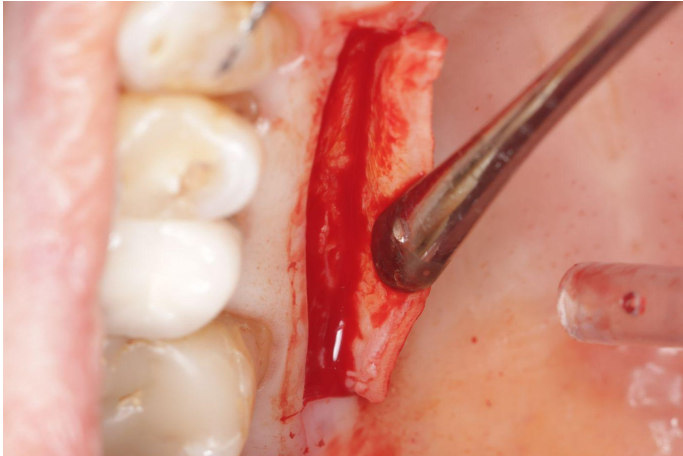
Check whether the stent is stable.



Check whether the patient can remove & place the stent themselves.



## Place the stent immediately after harvesting the graft

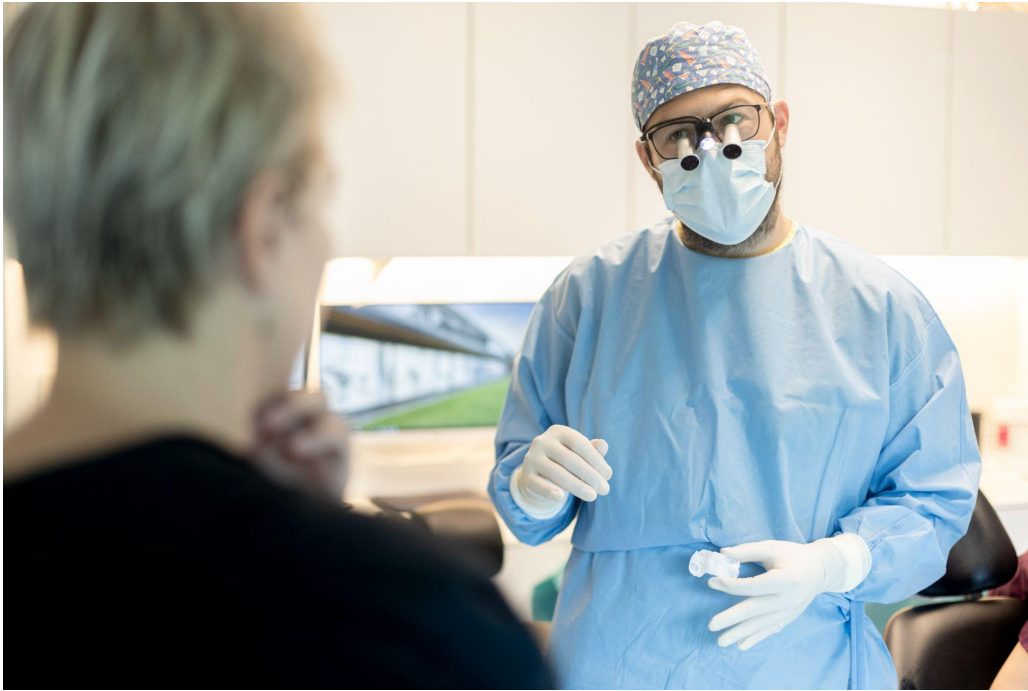

Immediately after harvesting the graft, cover the donor site with the stent. There is no need for suturing as the stent stabilizes the blood clot.

Without delays, you can continue with the recipient site surgery.

Heating the material — Creating the stent — Placing the stent — **Post-operative instructions**

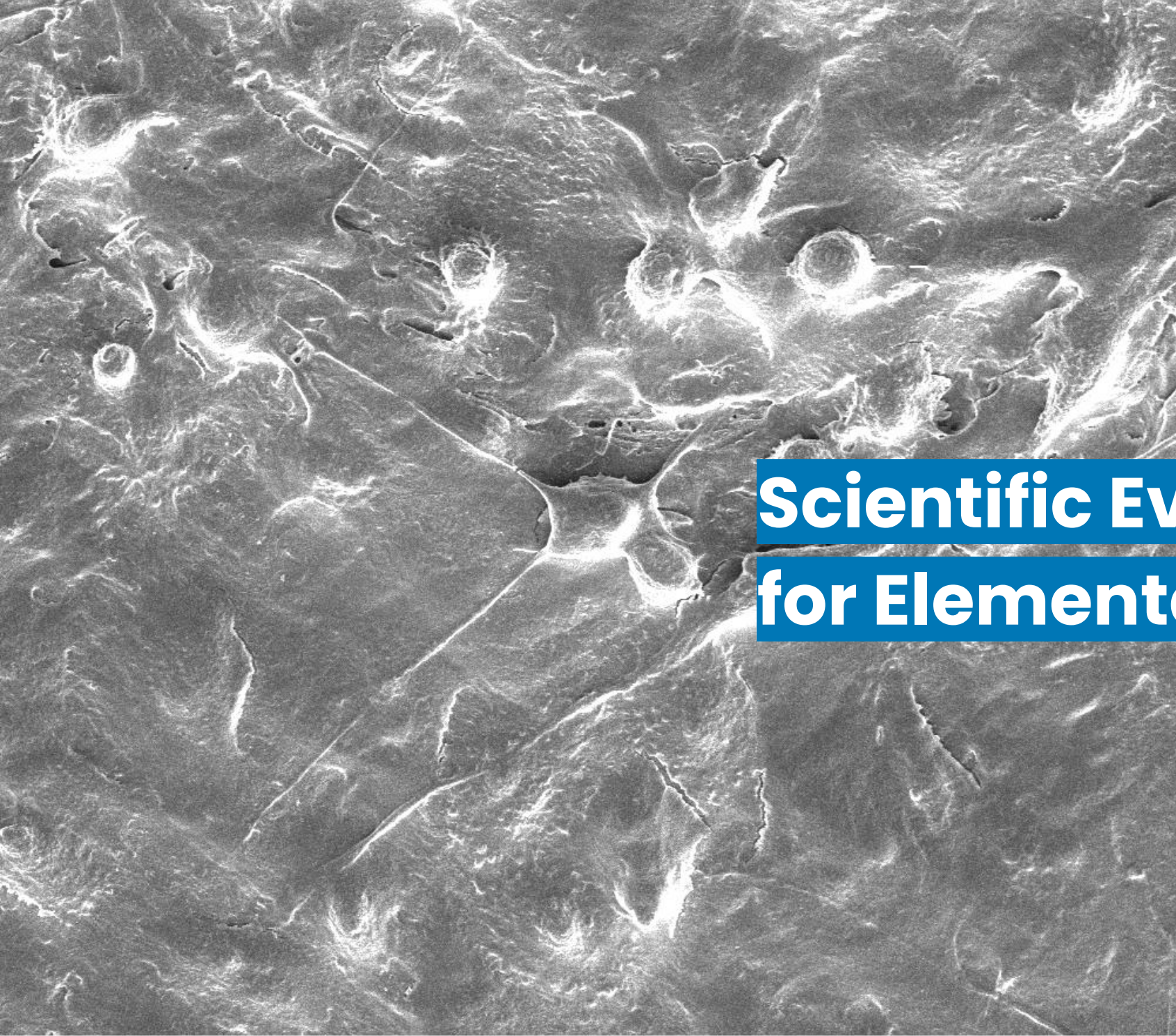
## Patients wear stent for 1 week



Stimulate patient compliance by informing them of the importance & benefits in terms of: pain management, healing, and general complications.

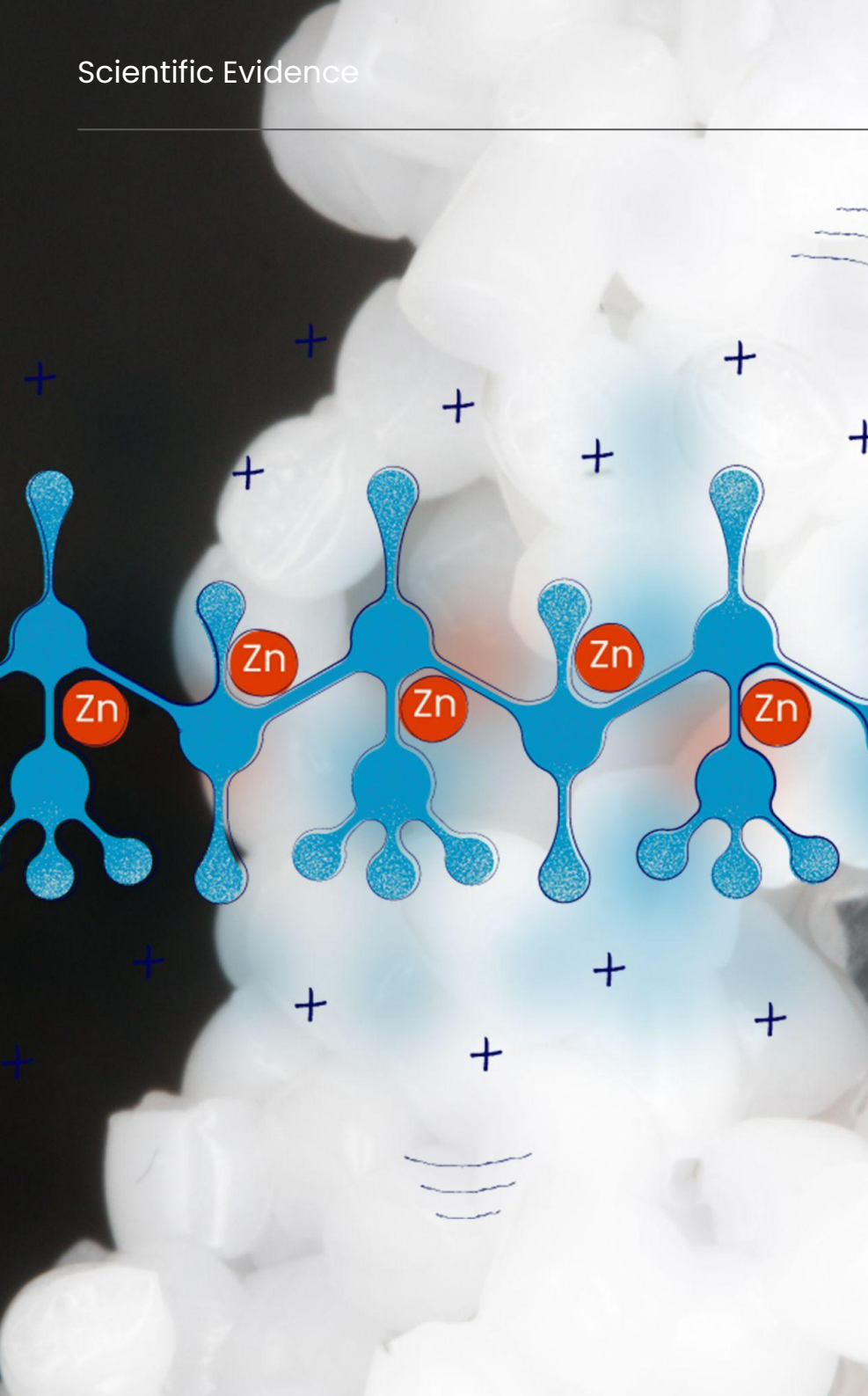


Inform them they should wear the stent as much as possible, up to 7 days. While undesirable, patients can remove & wash the stent.



# Scientific Evidence for Elemental

HV 5.00 kV	det ETD	mode SE	WD 4.5 mm	mag <input type="checkbox"/> 2 000 x	HFW 149 µm	50 µm
---------------	------------	------------	--------------	---	---------------	-------



#### PATENTED TECHNOLOGY

Elemental is based on a patented technology that infuses **zinc-oxide cations ( $Zn^{2+}$ )** into polymers.


This makes our material:

- ✓ **Biocompatible with human cell growth**
- ✓ **Bacteriostatic**

# Experiments performed by KU Leuven University demonstrating **superior biocompatibility**.

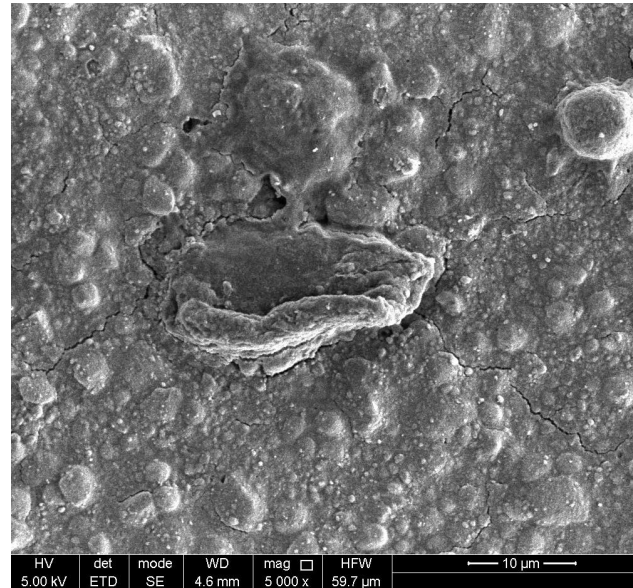
*Testing biocompatibility through measuring the adherence of human keratinocyte cells.*

## Elemental




*Elemental material fully covered in monolayer of healthy cells.*

## Composite



*Attached, unhealthy cells.*

## Glass Ionomer



*Monolayers attempting to grow.*

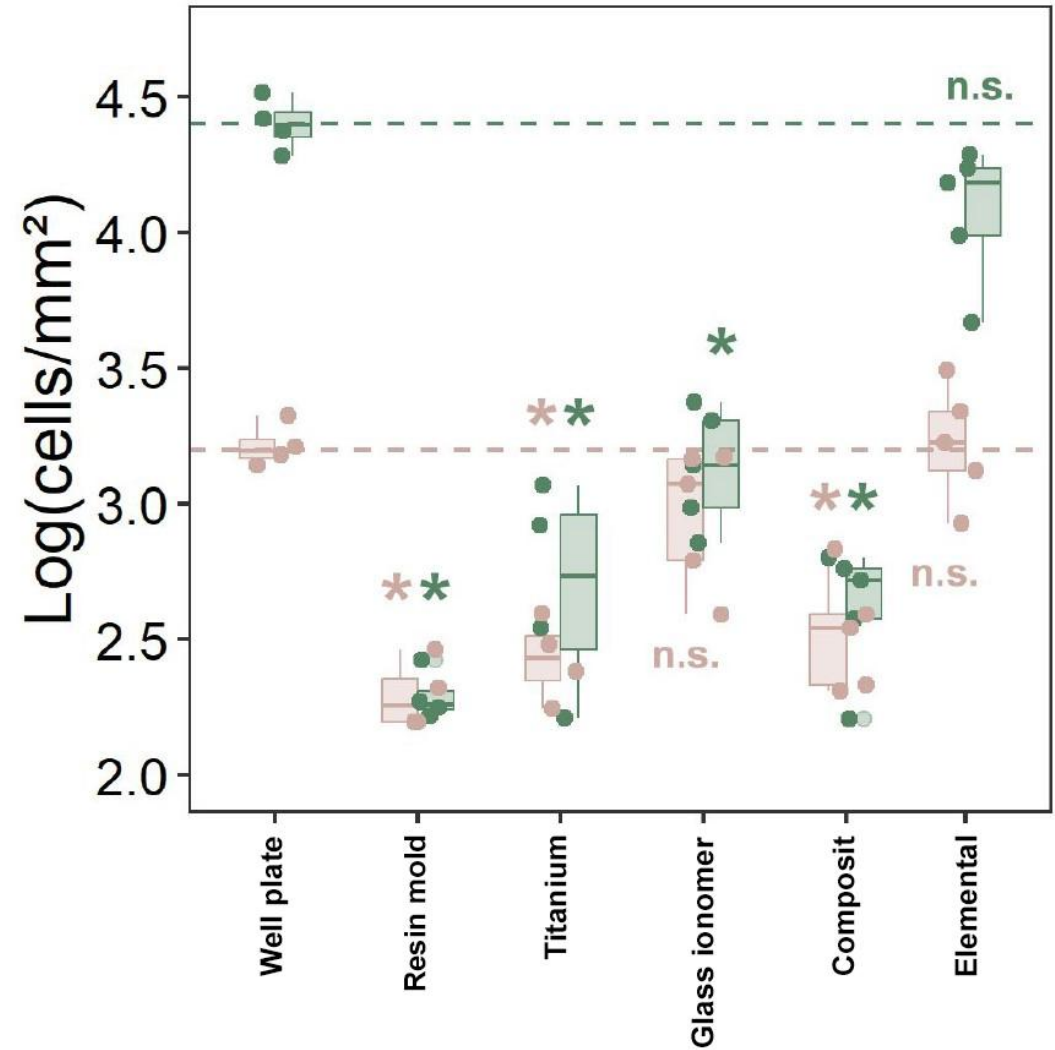
**KU LEUVEN** IN-VITRO TESTS

Experiments performed by KU Leuven University demonstrating **superior biocompatibility**.

Testing biocompatibility through measuring the adherence of human keratinocyte cells.

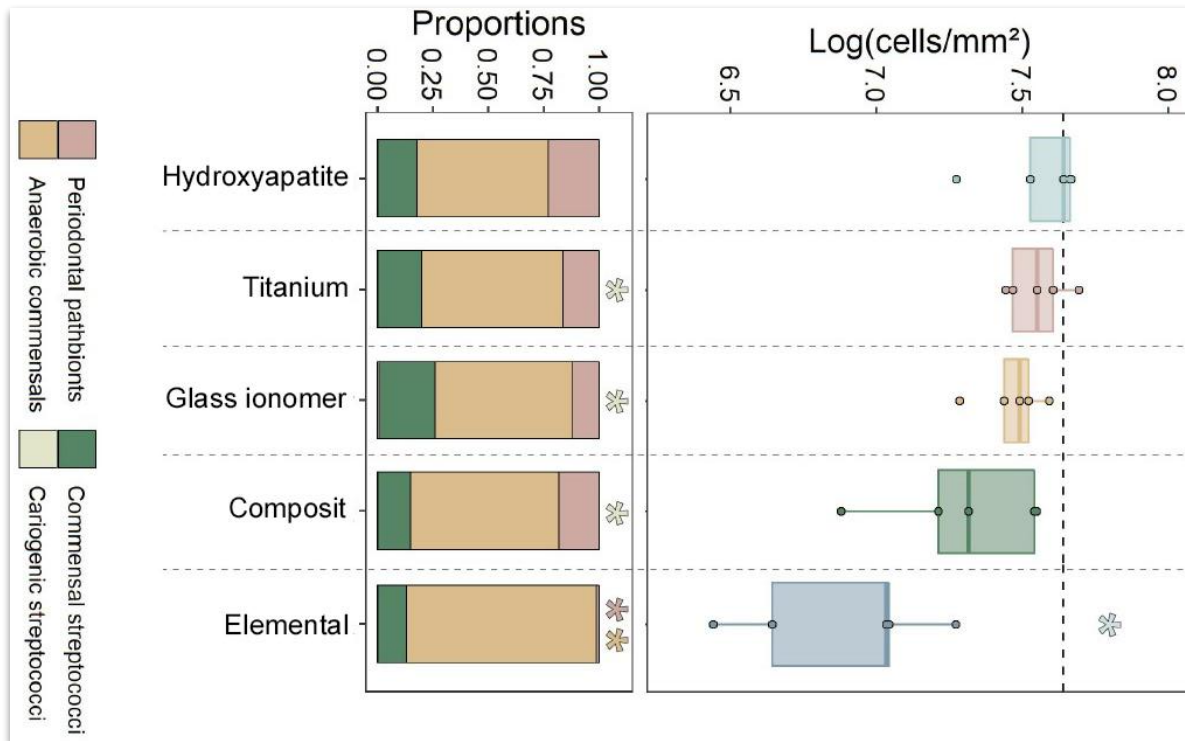


**Human keratinocyte cells growing best on Elemental.**



**KU LEUVEN** IN-VITRO TESTS

Experiments performed by KU Leuven University demonstrating **bacteriostatic properties**.



- ✓ **Oral biofilm growth inhibited on Elemental.**
- ✓ **The composition becoming less pathogenic.**

Clinical Oral Investigations  
<https://doi.org/10.1007/s00784-023-05171-3>

RESEARCH



## Pre-operative, chair-side Zn-containing surgical stents affect morbidity and wound healing after free gingival graft harvesting: a randomized clinical trial

Bahar Alkaya<sup>1</sup> · Hamza Gokhan Kayhan<sup>1</sup> · Andy Temmerman<sup>2</sup> · Mehmet Cenk Haytac<sup>1</sup> · Wim Teughels<sup>2</sup>

Received: 11 April 2023 / Accepted: 13 July 2023  
 © The Author(s), under exclusive licence to Springer-Verlag GmbH Germany, part of Springer Nature 2023

### Abstract

**Objective** To compare a pre-operatively, chair-side made, zinc-containing surgical stent (ZN) and suturing of a gelatin-based hemostatic agent (HA) on palatal wound healing and patient morbidity after free gingival graft surgery (FGG).

**Materials and methods** Sixty patients requiring FGG were randomly divided into two groups to receive either a ZN or a sterile HA sutured on the surgical area. Patients were evaluated at 1st, 3rd, 7th, 14th, 28th, and 56th days following surgery. Overall surgical time, donor site surgical time, postoperative pain (PP), delayed bleeding (DB), changes in dietary habits (DH), burning sensation (BS), completion of re-epithelialization (CE), and patients' discomfort (PD) were evaluated.

**Results** Donor site surgical time, PP, DB, DH, BS were statistically significantly lower in the ZN group together with faster completion of re-epithelialization compared to the HA group.

**Conclusion** Pre-operatively, chair-side made, zinc-containing surgical stents provided significant benefits for wound healing parameters and patients' postoperative morbidity after FGG harvesting.

**Clinical relevance** The results show that using Zn-containing palatal stent after free gingival graft surgery significantly reduces pain and patient morbidity during the postoperative period.

**Keywords** Zinc-embedded polymer · Free gingival graft · Wound healing · Palatal stent

### Introduction

Björn defined the free gingival graft (FGG) in 1963 to increase the amount of keratinized gingiva around teeth [1]. Sullivan and Atkins subsequently modified and improved the surgical approach [2]. The FGG approach is based on acquiring a palatal graft containing epithelium and connective tissue and placing it on a connective tissue bed prepared at the recipient site. It is routinely used and is a highly predictable procedure in mucogingival surgery [3]. In the presence of mucogingival problems such as insufficient attached gingival width, high frenulum attachments, and shallow vestibulum depth, FGGs are often used [4].

Numerous studies have described paresthesia, herpetic lesions, mucocoele, profuse bleeding, and severe postoperative discomfort after harvesting a FGG [3, 5–8]. The most pain is perceived at the palatal region after harvesting a FGG on the first postoperative day and returns to preoperative levels approximately 2 weeks later [9]. Hemostatics [10], bioactive substances [11], antibacterial and antiseptic agents [12], herbal products [5], platelet concentrates [7, 8], low-dose laser applications [13] cyanoacrylate tissue adhesives [14], hyaluronic acid [14], and palatal stents [15, 16] have been used at the palatal region to accelerate healing, prevent or decrease complications, and patient morbidity. However, the most optimal adjunct has not yet been identified. Mechanical protection of the post-harvesting palatal wound was first introduced by Langer and Langer [17]. It is the most common and accepted method and can be considered as the gold standard approach. Since it is known that the stability of the formed blood clot is one of the most crucial aspects for successful wound healing, several mechanical techniques have been used to protect the palatal clot until healing has occurred [18].

✉ Bahar Alkaya

<sup>1</sup> Department of Periodontology Faculty of Dentistry, Cukurova University, Adana, Turkey

<sup>2</sup> Department of Oral Health Sciences, KU Leuven & Dentistry (Periodontology), University Hospitals Leuven, Louvain, Belgium

Published online: 19 July 2023



## Pre-operative, chair-side Zn-containing surgical stents affect morbidity and wound healing after free gingival graft harvesting: a randomized clinical trial.

**Objective:** To compare a pre-operatively, chairside made, zinc-containing surgical stent (ZN) and suturing of a gelatin-based hemostatic agent (HA) on palatal wound healing and patient morbidity after free gingival graft surgery (FGG).

**Conclusion:** Pre-operatively, chair-side made, zinc-containing surgical stents provided significant benefits for wound healing parameters and patients' postoperative morbidity after FGG harvesting.



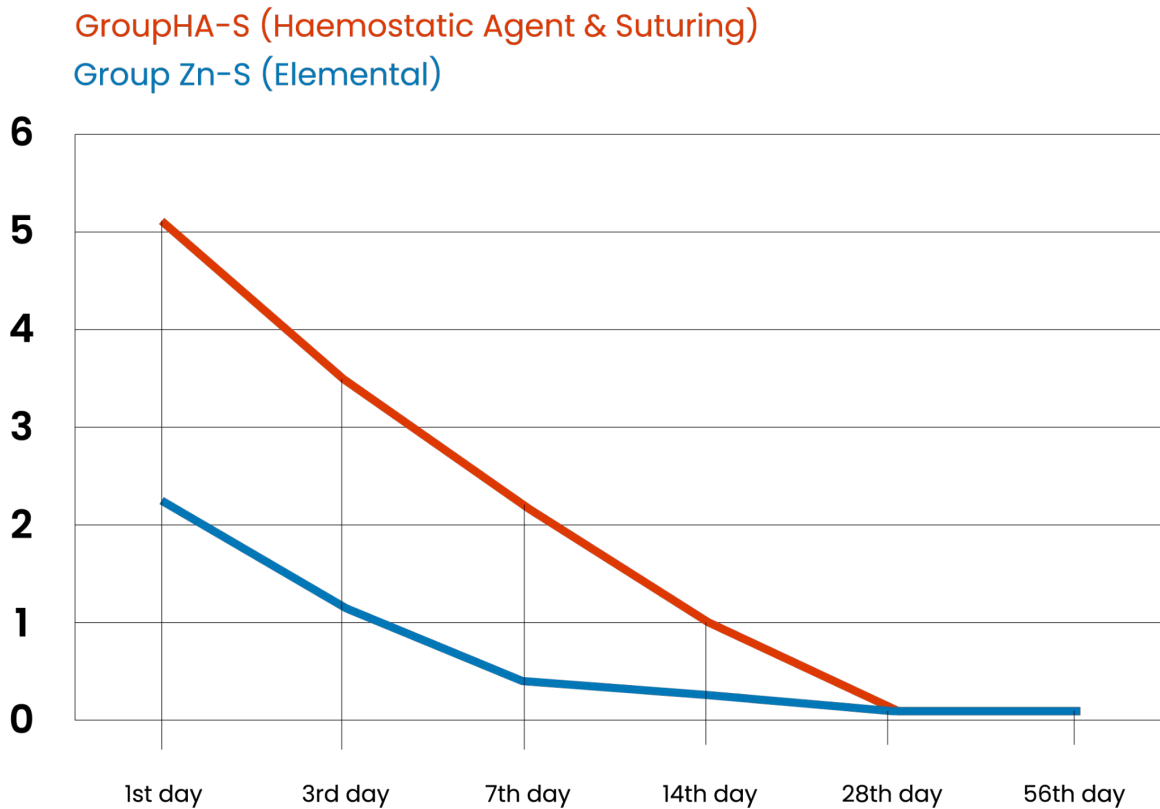
*“The study shows that Elemental minimizes pain, saves surgical time, and leads to spectacular healing.”*

Prof. Dr. Wim Teughels



# Minimizing post-operative pain

## Post-operative pain (VAS scores)



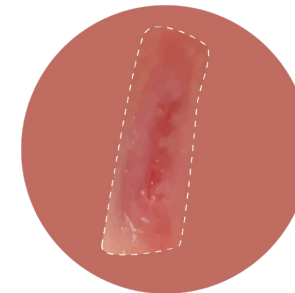
## Faster re-epithelialization

“Concerning pain reduction, the current study also revealed that the Zn-containing stent promoted a faster re-epithelialization rate.”

Number of patients experiencing partial re-epithelialization at 3rd day post-operative.

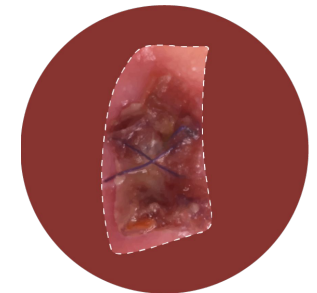
Elemental palatal stent

41.7%



Haemostatic agent & sutures

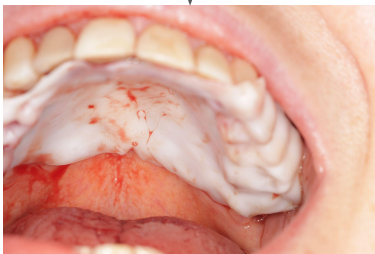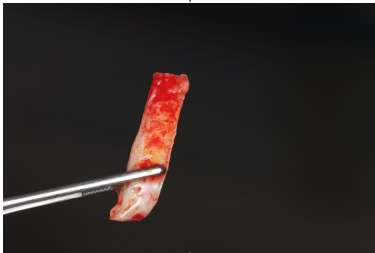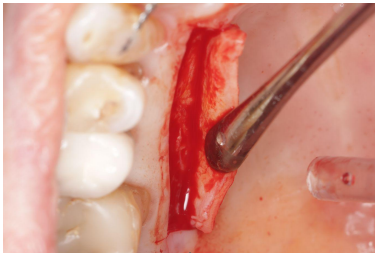
0%



Pre-operative, chair-side Zn-containing surgical stents affect morbidity and wound healing after free gingival graft harvesting: a randomized clinical trial. - Clinical Oral Investigations

## Reduced surgical time

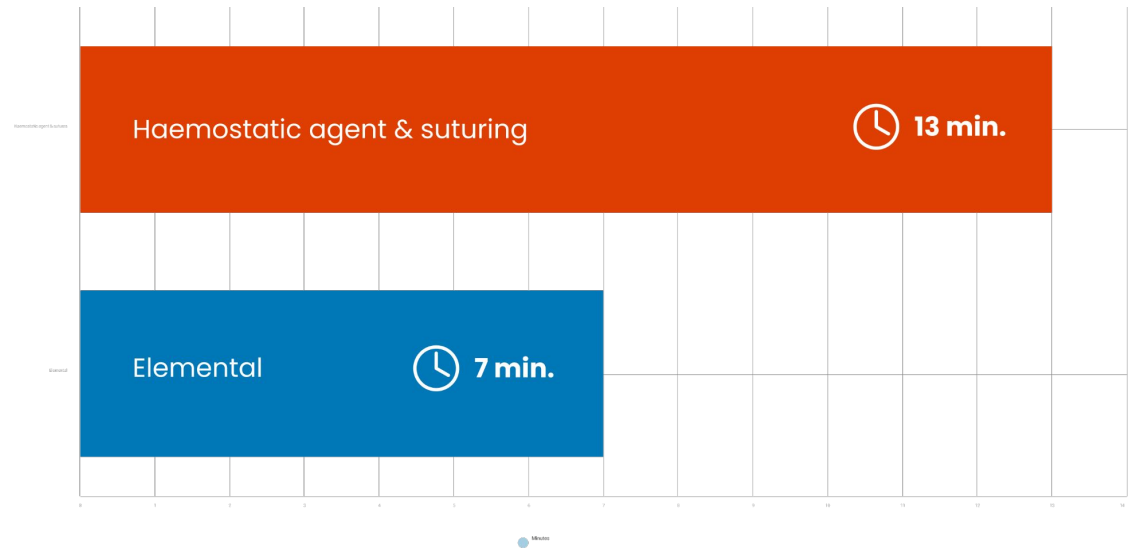
### No sutures on donor site



The stent is placed immediately after harvesting the graft.

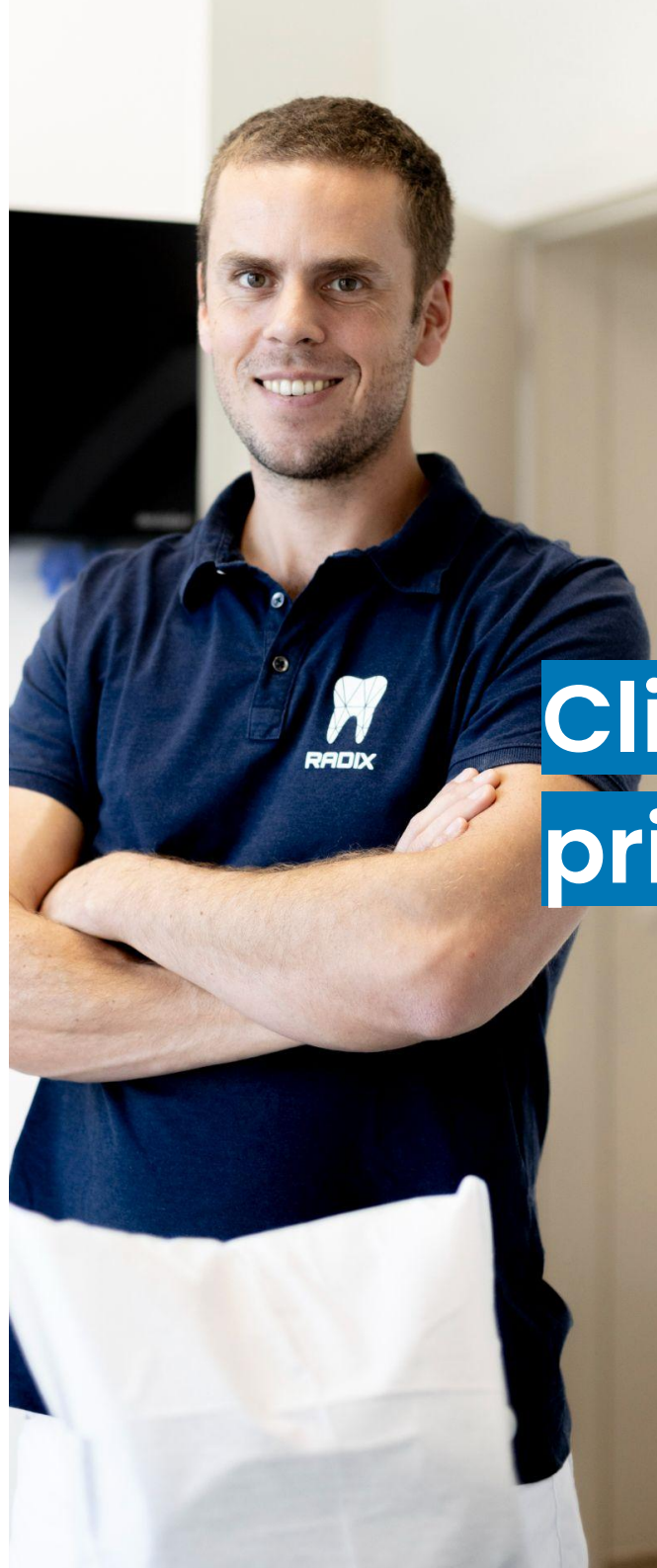
No sutures are used on the donor site.

### Average surgical time on donor site



*“Not having to suture the donor site is a massive time saver. I see colleagues save up to 15 minutes of surgical time per case.”*

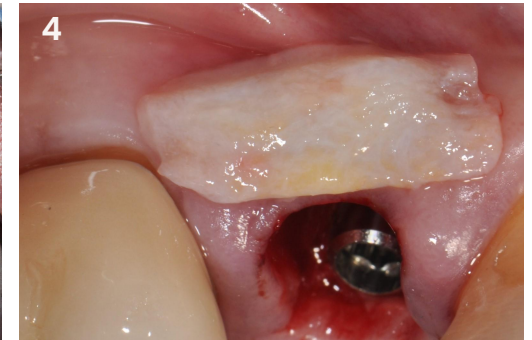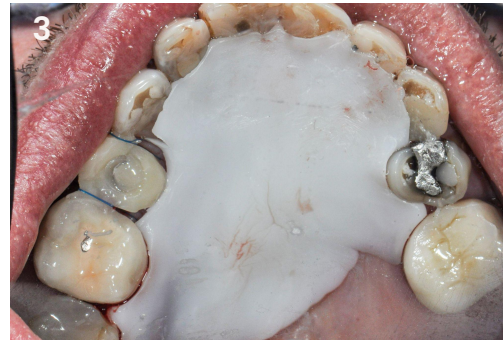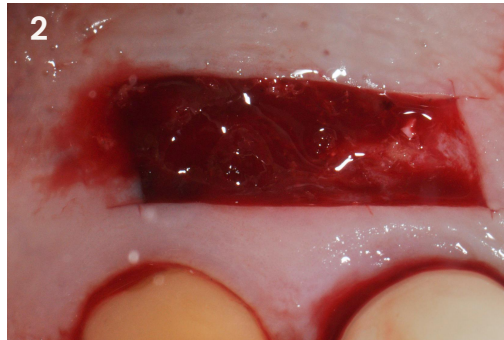
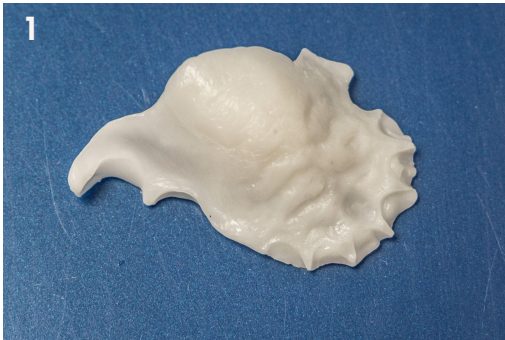Prof. Dr. Andy Temmerman



# Clinical cases in private practice

## Rutger Dhondt

Free Gingival Graft to increase keratinized mucosa around implant

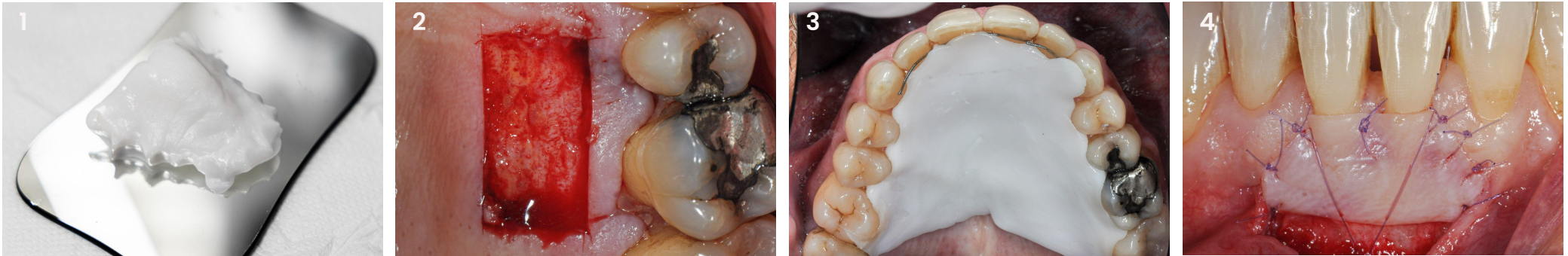


I create the stent right before the surgery (fig. 1) so I can place it immediately after harvesting the graft (fig. 2, 3).

At follow-up, patients only mention the recipient site. They don't even notice the donor site anymore.

## Rutger Dhondt

Free Gingival Graft to obtain increased keratinised tissue and root coverage

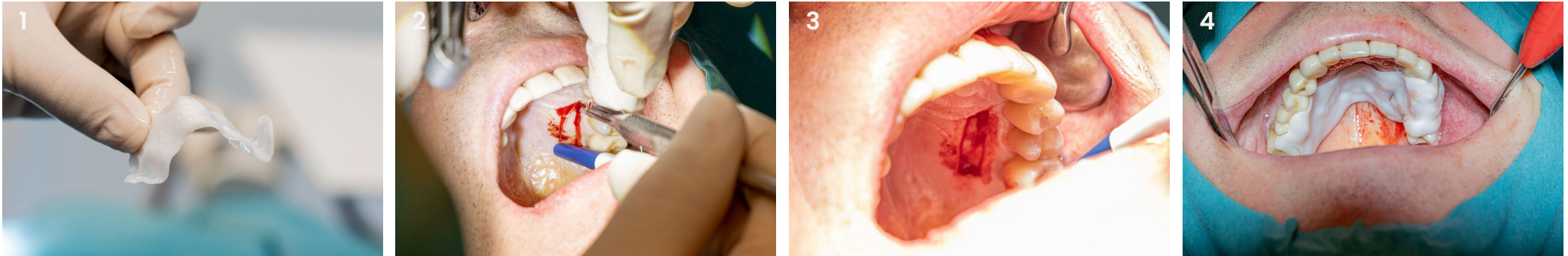


I create the stent right before the surgery (fig. 1) so I can place it immediately after harvesting the graft (fig. 2, 3).

At follow-up, patients only mention the recipient site. They don't even notice the donor site anymore.

## Bo Molemans

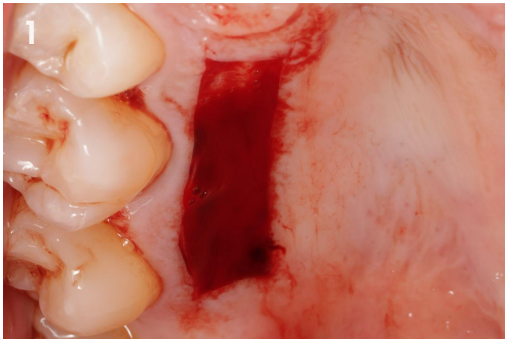Free Gingival Graft to obtain increased keratinised tissue and root coverage



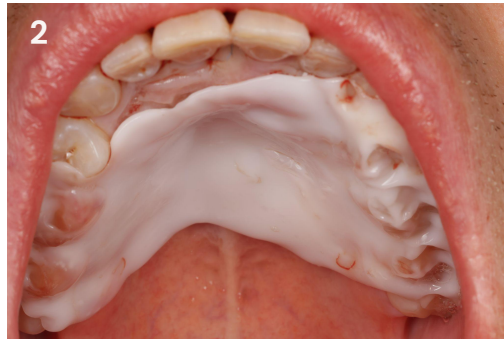The post-operative care on the donor site is reduced to a minimum, (fig. 3-4) saving 10-15 minutes of surgical time per case.

## Prof. Dr. Andy Temmerman

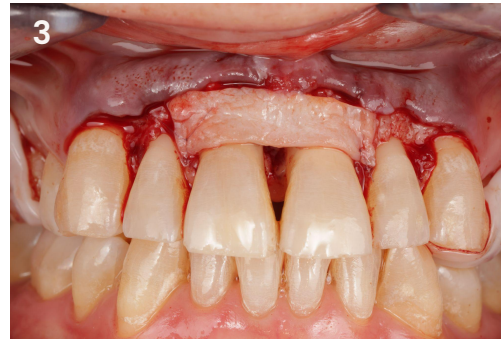Free Gingival Graft to obtain increased keratinised tissue and root coverage



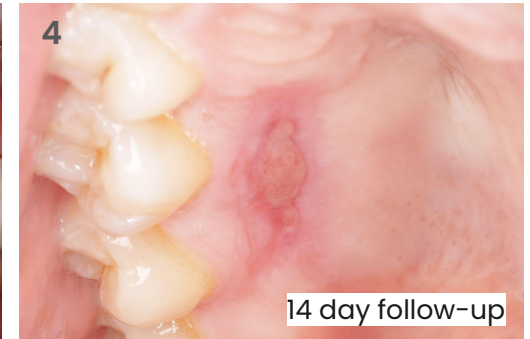1 The free gingival graft is harvested. No sutures are placed whatsoever.



2 The Elemental splint, created chairside before the surgery, is placed immediately after harvesting the graft.



3 Without delays, the graft is placed on the recipient site.



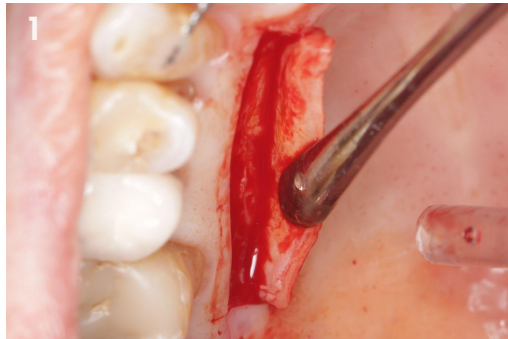
4 Follow-up at 14 days shows excellent healing and re-epithelialization. Patient experienced no pain.



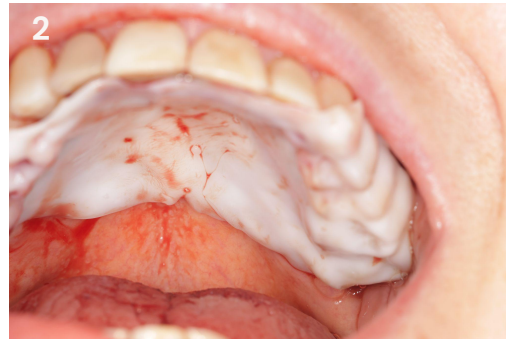Elemental dramatically reduces the post-operative discomfort (fig. 4,) which is of utmost importance, but also the surgical time by not having to suture the donor site (fig. 1-2)

## Prof. Dr. Andy Temmerman

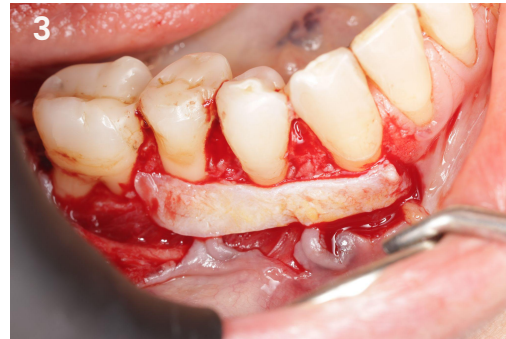Free Gingival Graft to obtain increased keratinised tissue and root coverage



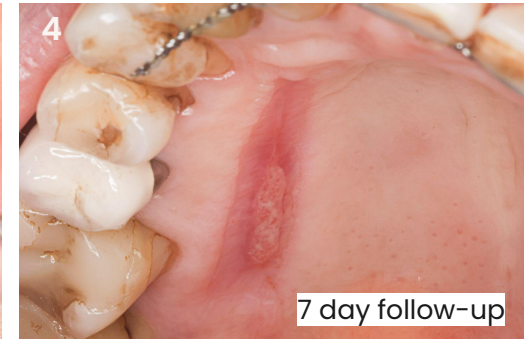1 The free gingival graft is harvested. No sutures are placed whatsoever.



2 The Elemental splint, created chairside before the surgery, is placed immediately after harvesting the graft.



3 Without delays, the graft is placed on the recipient site.



4 Follow-up at one week shows excellent healing and re-epithelialization. Patient experienced no pain.

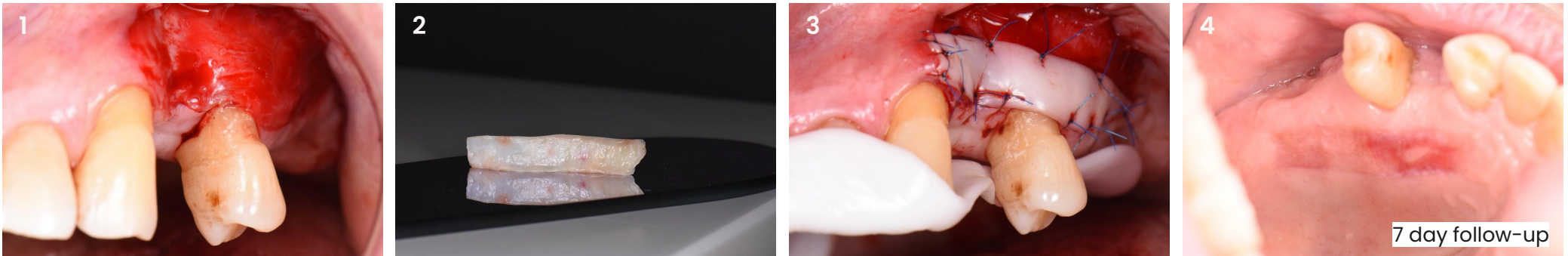


Elemental dramatically reduces the post-operative discomfort (fig. 4,) which is of utmost importance, but also the surgical time by not having to suture the donor site (fig. 1-2)



## Alexander De Greef

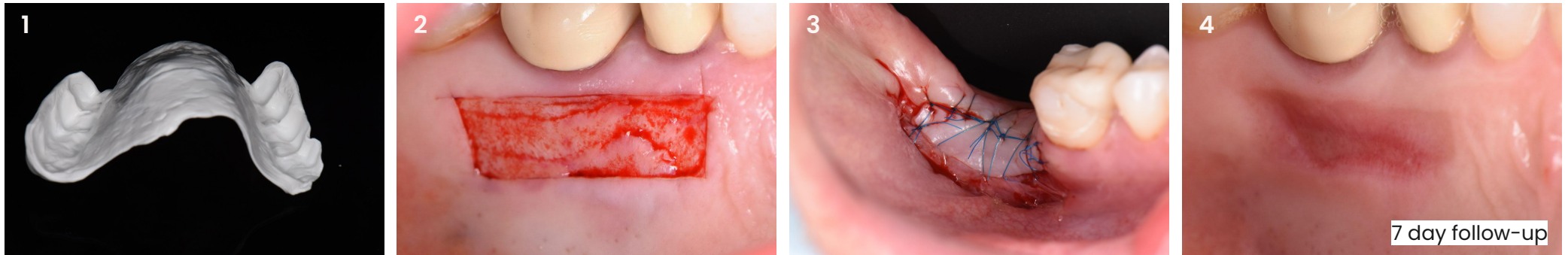
Free Gingival Graft to obtain increased keratinised tissue



The healing in the first days post-operative is spectacular (fig. 4), patients are not complaining about post-operative discomfort anymore.

## Alexander De Greef

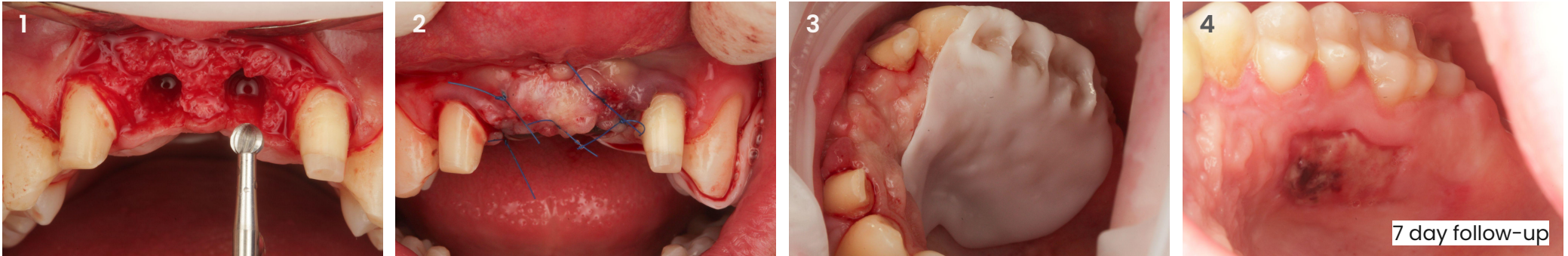
Free Gingival Graft to obtain increased keratinised tissue



The healing in the first days post-operative is spectacular (fig. 4), patients are not complaining about post-operative discomfort anymore.

## Guillaume De Moyer

Free Gingival Graft for soft tissue augmentation around implant site

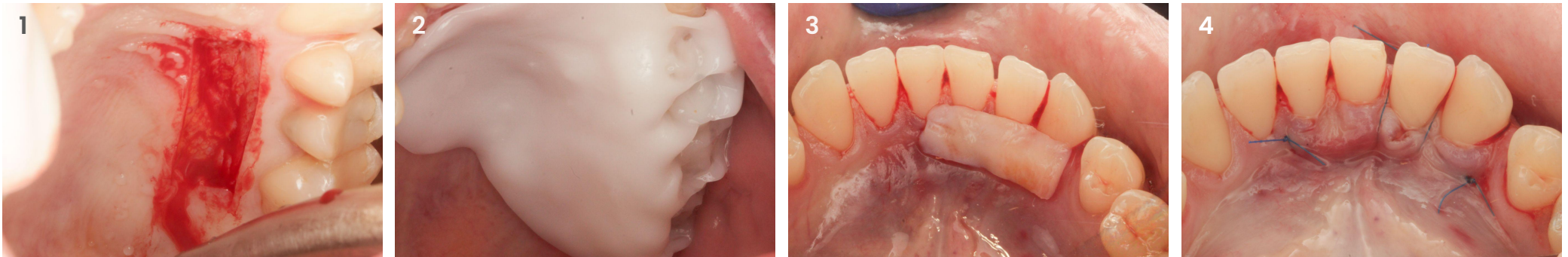


The Elemental stent immediately stabilizes the blood clot (fig. 2-3), allowing me to proceed with the recipient site much faster.

The healing after 1 week with Elemental resembles what I previously saw after 2 weeks. (fig. 4)

## Guillaume De Moyer

Free Gingival Graft to obtain increased keratinised tissue



The Elemental stent immediately stabilizes the blood clot and I don't have to sutures the donor site (fig. 2-3), allowing me to proceed with the recipient site much faster.



## Get started

Get in touch with a local distribution partner.

## Contact

Shane De Vreese

shane.devreese@withelemental.com

+32 475 47 08 85



**American Dental Systems**  
Germany & Austria



**Mediplus**  
Belgium & Luxembourg



**Dent-Med Materials**  
The Netherlands



**Ariston Dental**  
Greece



**Karr Dental**  
Switzerland



**Pred Laboratoires**  
France



**Unident**  
The Nordics



**Swallow Dental**  
United Kingdom



**Gursk Medica**  
Romania



**Botiss Hungary**  
Hungary